Int. J. Cancer: **122,** 711–718 (2008)
© 2007 Wiley-Liss, Inc.

SHORT REPORT

Clinical, histopathologic, molecular and therapeutic findings in a large kindred with gastrointestinal stromal tumor

Eric P. Kleinbaum[1], Alexander J.F. Lazar[2,3], Elena Tamborini[4], John C. Mcauliffe[1], Pamela B. Sylvestre[5], Thomas D. Sunnenberg[6], Louise Strong[7], Lei L. Chen[1], Haesun Choi[8], Robert S. Benjamin[1], Wei Zhang[2] and Jonathan C. Trent[1,3]*

[1]*Department of Sarcoma Medical Oncology, University of Texas, M. D. Anderson Cancer Center, Houston, TX*
[2]*Department of Pathology, University of Texas, M. D. Anderson Cancer Center, Houston, TX*
[3]*Sarcoma Research Center, University of Texas, M. D. Anderson Cancer Center, Houston, TX*
[4]*Department of Pathology, Fondazione IRCCS Istituto Nazionale dei Tumori, Milan, Italy*
[5]*Department of Pathology, Methodist University Hospital, Memphis, TN*
[6]*Sacred Heart Medical Oncology, Pensacola, FL*
[7]*Department of Cancer Genetics, University of Texas, M. D. Anderson Cancer Center, Houston, TX*
[8]*Department of Diagnostic Imaging, University of Texas, M. D. Anderson Cancer Center, Houston, TX*

Germ-line mutations in the *KIT* receptor tyrosine kinase gene have been described in families with a propensity to develop gastrointestinal stromal tumor (GIST). There is limited information from large kindreds regarding median age at diagnosis, detailed histopathology, clinical effects of imatinib therapy and chromosomal abnormalities of the *KIT* gene. We identified a large kindred with GIST. Each family member was interviewed and appropriate medical records and radiographic imaging were obtained. Archival tumor tissue was obtained to confirm diagnosis, extract genomic DNA and perform fluorescent *in situ* hybridization cytogenetics of the *KIT* gene. Fifteen of 79 individuals with GIST were identified in this kindred. There were 8 males, the mean age at diagnosis was 53.9 (range 45–71) years. Histopathology revealed microscopic proliferation and nodularity in the myenteric plexus, spindled morphology, diffuse Kit but variable CD34 staining and low mitotic rates in the setting of metastatic disease. A deletion of codon 579 in exon 11 of the *KIT* gene was identified in tumor and normal tissue of this family. Mutation and cytogenetic analysis revealed homozygous loss of the wild-type *KIT* sequence in tumor from one individual. Four of 4 individuals treated with imatinib are alive and without progression while 9 of 11 individuals not treated with imatinib are deceased. This study describes a kindred with a propensity to develop GIST in an autosomal dominant pattern. Germ-line deletion of KIT codon 579 in GIST is associated with clinical benefit from imatinib, limited utility of mitoses to predict malignant potential, and a novel homozygous deletion of this codon in one individual.
© 2007 Wiley-Liss, Inc.

Key words: mutation; sarcoma; therapy; genotype; Gleevec

Gastrointestinal stromal tumors (GISTs) represent the most common mesenchymal tumor of the gastrointestinal tract. The clinical behavior of GIST varies widely from an indolent tumor to a rapidly progressive and fatal disease. These tumors are thought to arise from the Interstitial Cells of Cajal (ICC), cells that function in the intrinsic nervous system of the gastrointestinal tract[1] and express the KIT receptor tyrosine kinase in 95% of cases.[2]

Although most of these tumors develop sporadically, small GIST kindreds reported so far appear to likely occur in an autosomal dominant manner with multiple lesions on initial diagnosis of disease.[3] Most kindreds with familial GIST are stricken with a germ-line mutation in the *KIT* gene on chromosome 4 but there has been a report of a family with a *PDGFRA* gene mutation.[3–13] In families with GIST, the mutational site within *KIT* occurs most commonly in the juxtamembrane domain encoded by exon 11 (Table I). Since most of these kindreds are small and were described before the use of imatinib therapy, there are gaps in the knowledge of this entity. For instance, the median age at diagnosis has been described in one study to decrease in successive generations possibly because of better diagnostic imaging or evolving genetic stability.[12] This observation has not been reported in other studies and has not been confirmed in another large kindred. Additionally, histopathologic evaluation of GISTs resected from kindreds has not been evaluated in terms of the consensus criteria for risk stratifications of GIST using mitotic rates and tumor size.[14] Moreover, the efficacy of imatinib therapy of multiple members of large kindred remains largely unknown. There are no existing reports of cytogenetic analyses of the *KIT* locus in GISTs from individuals of a GIST-prone kindred.

In our study, we sought to answer these questions by describing our findings in a kindred with 15 members with GIST (Fig. 1). We describe herein the clinical presentation, pattern of inheritance, histopathologic appearance of the tumors, clinical or radiographic efficacy of imatinib mesylate (IM; Gleevec, Novartis, Basel, Switzerland) therapy and molecular observations. Additionally, we describe a novel homozygous deletion of codon 579 in exon 11 of the *KIT* gene.

Methods

Patients

With informed consent under a protocol approved by the Institutional Review Board, 32 family members released their medical records for review were interviewed in person or by telephone, and had a physical examination for skin lesions when possible. Medical records, paraffin-embedded tissue and radiographic studies were obtained for patients with a history of GIST or symptoms consistent with a possible GIST. Each living family member was sent an extensive detailed medical questionnaire. Actuarial analysis was performed using SPSS software (SPSS, Chicago).

Histopathology

Tumor was available from 4 of 15 family members with GIST (III–II, III–III, IV–III and IV–IV) and independently reviewed by a sarcoma pathologist (AJFL). Each specimen was evaluated for the presence of KIT, CD34, smooth muscle actin, desmin, pan-

Grant sponsors: NIH/NCI, Institutional Physician-Scientist Award, The Amschwand Sarcoma Cancer Foundation (JCT); Grant number: 1K23CA109060-02; Grant sponsor: NCI Cancer Center; Grant number: CA-16672.
***Correspondence to:** Department of Sarcoma Medical Oncology, The University of Texas, M. D. Anderson Cancer Center, 1515 Holcombe Boulevard, Suite FC11.3032, Unit 450, Houston, TX 77030, USA.
Fax: +713-794-7134. E-mail: jtrent@mdanderson.org
Received 23 May 2007; Accepted after revision 10 July 2007
DOI 10.1002/ijc.23137
Published online 17 October 2007 in Wiley InterScience (www.interscience.wiley.com).

TABLE I – REPORTED GIST KINDREDS WITH MUTATION SITE AND ASSOCIATED CONDITIONS

Kit exon	Mutation	Family	Associated conditions
8	del419D	Hartmann *et al*., (Marshall *et al*.)	Mastocytosis, achalasia
11	V559A	Li *et al*., Maeyama *et al*., Nishida et al., Beghini *et al*.	Hyperpigmentation, urticaria pigmentosa, nevi, mastocytosis
11	W557R	O'Brien *et al*., Hirota *et al*., Robson *et al*., Chen *et al*.	Hyperpigmentation, achalasia
11	Ins576QL577	Carballo *et al*.	Hyperpigmentation
11	Del579	Kleinbaum *et al*., Tarn *et al*.	Hyperpigmentation, second cancers?
13	K642E	Isozaki *et al*.	None
17	D820Y	Hirota *et al*., O'Riain *et al*.	Achalasia
PDGFR-α(exon 18)	D846Y	Chompret *et al*.	None
Wild-type or unknown	NA	Carney *et al*., Carney *et al*.	Paraganglioma-GIST, Carney's Triad (paraganglioma, pulmonary chondroma)

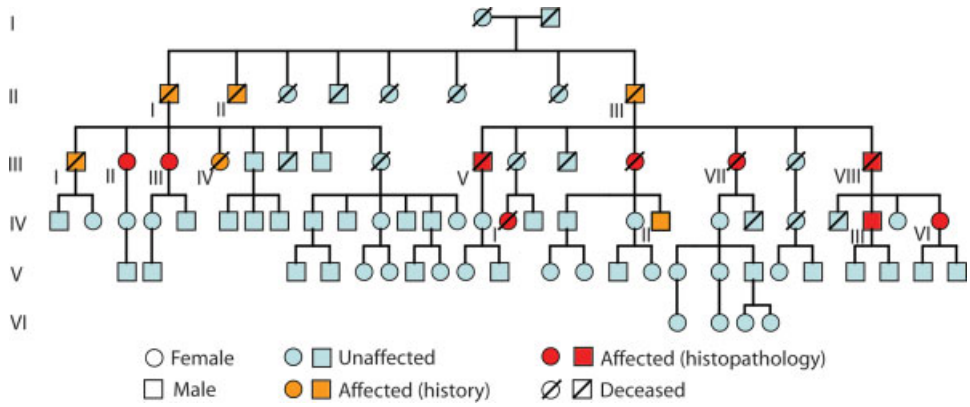

FIGURE 1 – Pedigree of GIST kindred. Female individuals are denoted with circles, males with squares and a diagonal line indicated a deceased individual. GIST diagnosis was confirmed by histopathology (red), supported by family history and medical records (orange) or unaffected (light blue).

cytokeratin and S-100 protein using standard clinical immunohistochemical techniques. The gross maximal tumor size and number of mitoses per 10 high-powered field were recorded. Based on these criteria the tumor was classified as low, intermediate or high risk per consensus guidelines.[14]

Genomic sequence analysis of KIT *and* PDGFR-α

DNA was isolated from microdissected, paraffin-embedded tissue or from peripheral blood mononuclear cells (PBMCs) by using a QIAamp DNA minikit (Qiagen, Valencia, CA) according to the manufacturer's instructions. Nucleotide sequencing was analyzed with a 3730 × 1 DNA analyzer from Applied Biosystems, Foster City, CA. The genomic DNA sequence of exons 9, 11, 13, 15 and 17 was analyzed as previously described in all available GIST specimens and PBMCs.[15]

Fluorescent in situ *hybridization*

Fluorescent *in situ* hybridization (FISH) analysis of representative areas from 2 surgical specimens (individual III–II and IV–III) was performed to define the allelic status of the *KIT* genes. BAC clone RP11-586A2 (*KIT* gene, 4q12) was labeled with spectrum green (SG; Vysis, Downers Groove, IL) and CEP4 was labeled with spectrum orange (SO; Vysis) to evaluate chromosome 4 integrity and copy number as previously described.[16] The samples were stained with DAPI II antifade (Vysis) to visualize nuclei and the probe mixtures evaluated under microscopy. The slides were visualized using a camera-equipped Zeiss Axioscope with DAPI, SG and SO filters (Vysis). The signals were counted in more than 40 nuclei per slide under 600× and 1,000× magnification and a consistent cytogenetic pattern was present in more than 90% of cells.[17,18]

Findings

Patients and histopathology

We report a kindred of 15 individuals with the diagnosis of GIST (Fig. 1 and Table II). We did not find any evidence to support a sex-linked pattern of inheritance in this kindred since 8 of the affected individuals were male while 7 were female. Additionally, the 15 individuals with GIST had 32 combined siblings, supporting an autosomal dominant pattern of inheritance. We noted family members with melanocytic nevi and one with hyperpigmentation. The mean age at diagnosis was 53.9 years (range 37–71 years) overall and was 54.5 years (range 37–71 years) in generation III, but 55 years (range 45–63 years) in the more recent generation IV. We found that the probability of diagnosis with GIST was low (0.077) before the age of 40 but began increasing such that the probability of having GIST by the age of 50 was 0.462 (Table III). Surprisingly, individuals III–II and III–VI were diagnosed when older than 70 years. The small intestine or the stomach were the most common sites of primary tumor formation. Two individuals were found to have pulmonary metastases, an uncommon feature in sporadic GIST but one observed in animal models of spontaneous GIST driven by somatic *KIT* mutations.[19]

Surgical resection (Fig. 2) and histopathology (Fig. 3) typically revealed multifocal tumors arising from the hyperproliferative, nodular myenteric plexus. Additional histopathologic findings included spindled morphology in all cases, diffuse KIT staining, variable CD34 staining and variable mitotic rates. Individual IV–III was found to have no expression of CD-34 in any areas of the tumor that were evaluated. Mitotic rates tended to be higher in generation IV compared with III (30 *vs*. 2 mitoses per hpf) and were highest in individual IV–IV (30 mitoses per 50 hpf) who had multiple large liver metastases, but lower in individual IV–III

TABLE II – CHARACTERISITICS OF 15 INDIVIDUALS WITH GIST FROM A LARGE KINDRED

Case	Age at diagnosis	Gender	Clinical presentation	Diagnostic evaluation	Tumor locations	Dermatologic manifestations	Imatinib therapy	Result of therapy	Status
II–I	45	M	Hematuria	Laparotomy	Small intestine	ND	N	NA	DOD
II–II	ND	M	ND	Laparotomy	Small intestine	ND	N	NA	DOD
II–III	ND	M	Hematuria	Laparotomy	Small intestine	ND	N	NA	DOD
III–I	45	M	ND	Laparotomy	Small intestine	ND	N	NA	DOD
III–II	70	F	Abdominal pain	EGD; CT; laparotomy	Stomach; small intestine; liver	Junctional melanocytic nevus	Imatinib	4-year disease-free interval	AWD
III–III	58	F	GI hemorrhage	Laparotomy	Stomach; small intestine	Junctional melanocytic nevus	Imatinib	Regression by EGD	AWD
III–IV	45	F	ND	ND	Small intestine	ND	N	NA	DOD
III–V	65	M	Abdominal pain; perforated bowel	Laparotomy	Small intestine	ND	N	NA	DOD
III–VI	71	F	Abdominal pain	Laparotomy	Stomach; small intestine; colon; liver	ND	Chemo-therapy	Progression	D
III–VII	37	F	Abdominal pain; weight loss	laparotomy	Small intestine; liver; lung	ND	Chemo-therapy	Progression	DOD
III–VIII	45	M	GI hemorrhage	Laparotomy	Small intestine	ND	N	NA	DOD
IV–I	60	F	Abdominal pain	EGD; colonoscopy; laparotomy	Stomach; small intestine	ND	N	NA	D
IV–II	63	M	Abdominal pain; increased girth	EGD	ND	None	ND	ND	AWD
IV–III	52	M	GI hemorrhage	Laparotomy	Small intestine; lung	None	Imatinib	Regression by CT	AWD
IV–IV	45	F	Abdominal fullness; increased girth	CT; laparotomy	Small intestine; liver	Hyperpigmentation	Imatinib	Regression by CT	AWD

Abbreviations: M, male; F, female; ND, no data; EGD, esophagogastroduodenoscopy; CT, computed tomography; N, no; NA, not applicable; DOD, dead of disease; D, dead; N, none; AWD, alive with disease.

TABLE III – ACTUARIAL ANALYSIS OF AGE OF DIAGNOSIS OF GIST IN A KINDRED WITH GERM-LINE MUTATION IN EXON 11 OF THE *KIT* GENE

Age (years)	Individuals with GIST	Cumulative number of individuals with GIST[1]	Cumulative probability of diagnosis with GIST	Standard error
20	0	0	0.000	0.000
30	1	1	0.077	0.074
40	5	6	0.462	0.138
50	2	8	0.615	0.135
60	3	11	0.846	0.100
70	2	13	1.000	0.000

[1]Two individuals did not have available age at diagnosis.

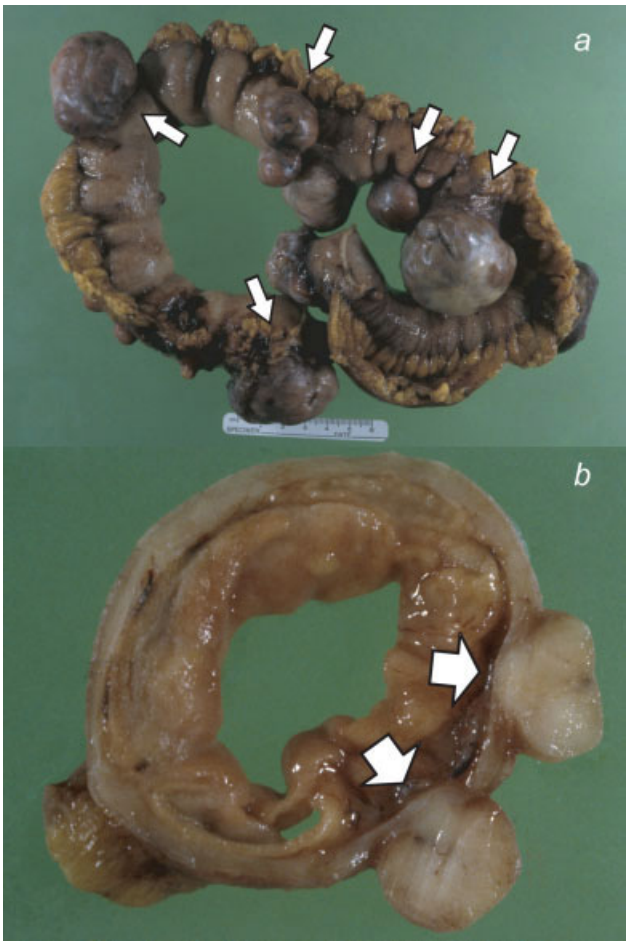

FIGURE 2 – Gross pathology after surgical resection of synchronous primary GISTs from patient IV–III. (*a*) Multiple GISTs of the small bowel with arrows illustrating multiple tumor nodules. (*b*) Magnified view of small bowel with arrows illustrating cross-section of 2 tumor nodules that appear to be arising from the myenteric plexus.

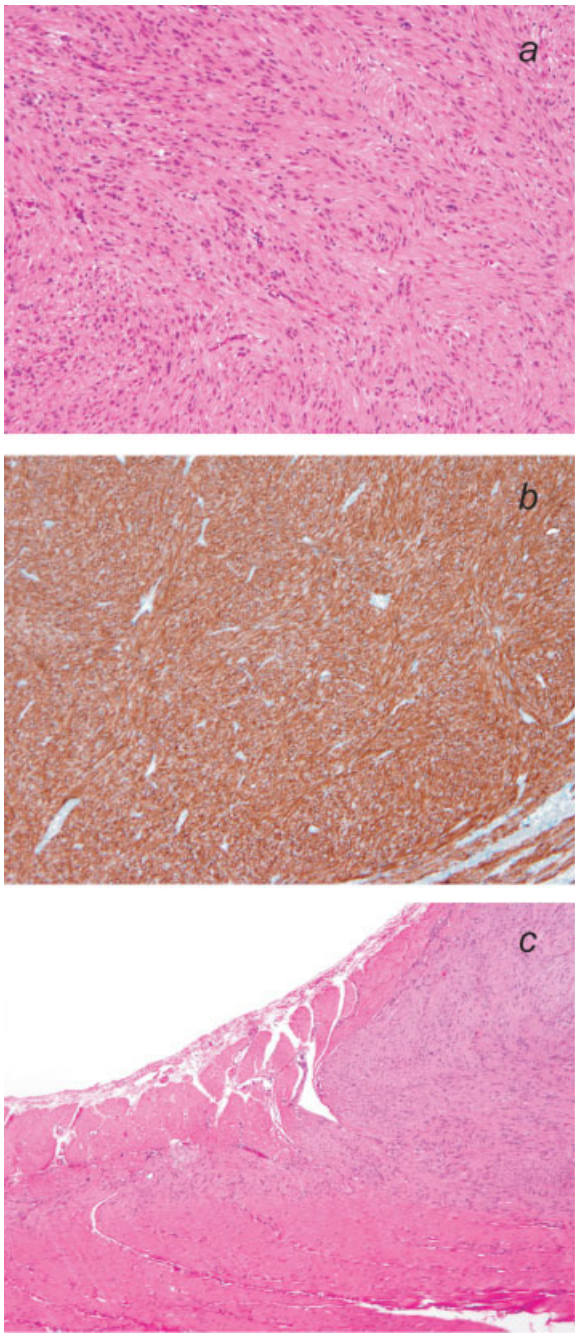

FIGURE 3 – Representative histopathologic findings of a GIST from an individual from a GIST-prone kindred (IV–III). (*a–c*) H&E of a GIST in the colon reveals spindle cells with abundant pink cytoplasm (*a*) and diffuse membranous and cytoplasmic reactivity for KIT on immunohistochemistry (*b*). Diffuse hypertrophy of enteric plexi was noted with numerous small nodules ranging up to 3 mm (*c*). Interestingly, the small intestinal nodules stained strongly for CD117 but not CD34 in this case (data not shown).

(5 mitoses per 50 hpf) who also had conspicuous metastatic disease.

Mutation analysis

We performed direct sequencing of *KIT* genomic DNA (exons 9, 11, 13, 15 and 17) on tumor, uninvolved paraffin-embedded tissue specimens from the 4 affected members. The germ-line deletion in this kindred was found in exon 11 resulting in an in-frame deletion of 3 base pairs at position 1756–1758 (GAT) with loss of codon 579 in the cytoplasmic juxtamembrane region of *KIT*. This deletion was observed in an adjacent normal tissue in individuals III–II, III–III and IV–IV (Fig. 4*a*, middle panel represents peripheral blood from IV–IV). This same mutation was observed in tumor tissue from individuals III–II, III–III and IV–IV. Other than the deletion in codon 579, no other mutations were observed in *KIT* exon 9, 11, 13, 15 or 17, or in the PDGFR-α exon 12 or 18 of these 3 individuals. Interestingly, the tumor from one individual

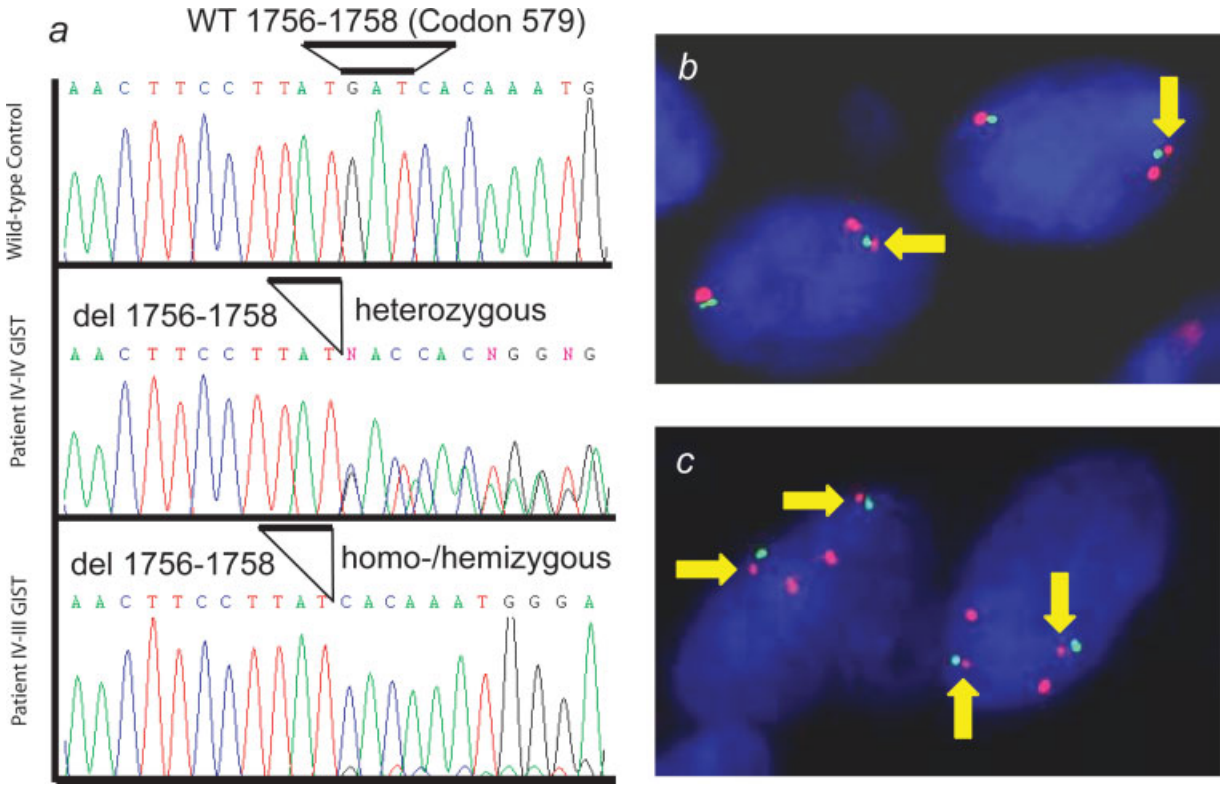

FIGURE 4 – Homozygous/hemizygous deletion at codon 579 (GAT) results in the loss of heterozygosity in a GIST from patient IV–III. (*a*) Upper panel, wild-type *KIT* gene from normal control DNA; middle panel, peripheral blood mononuclear cells from patient IV–III showing germ-line heterozygous deletion of 3 base pairs at codon 579 (GAT) with subsequent 3 base pair frame shift in exon 11; lower panel, tumor from the same patient shows loss of heterozygosity with deletion of GAT at codon 579 in *KIT* exon 11. Representative FISH analysis of individuals III–II and IV–III from this kindred. Upper panel (*b*), individual III–II displays 2 copies of the *KIT* gene having 2 different centromeric chromosome 4 pattern. Lower panel (*c*), individual IV–III displays 2 copies of the *KIT* gene associated to the same centromeric chromosome 4 pattern.

(IV–III) displayed loss of heterozygosity at codon 579 with no detectable wild-type *KIT* gene (Fig. 4*a*, lower panel) while adjacent normal tissue remained heterozygous with the same mutation as that of normal and tumor from individuals III–II, III–III and IV–IV. We next sought to determine whether the loss of heterozygosity in the tumor was due to loss of chromosome 4 or loss of the wild-type *KIT* gene.

Kit *and* PDGFRA *FISH analysis*

To determine the nature of the loss of heterozygosity of the mutant *KIT* gene, we performed chromosome FISH analysis of tumor from individuals III–II and IV–III. We found that both individuals retained 2 copies of both the *KIT* (Figs. 4*b* and 4*c*, in green) and *PDGFR*-α genes (data not shown) associated to 2 chromosome 4 centromeric signals (in red). In both patients small red signals (indicated by yellow arrows) lower in intensity are present, representing a possible chromosomal rearrangement involving a small portion of the chromosome 4 centromere. While in patient III–II (Fig. 4*b*, upper panel) 2 distinct patterns of chromosome 4 were observed, one consistent with the wild-type and one consistent with an abnormal chromosome 4 with a possible rearrangement involving a small portion of the centromere. However, patient IV–III (Fig. 4*c*, lower panel C) was found to have only the abnormal chromosomal pattern with 2 abnormal chromosome 4 centromeric probes. According to these results, it is possible that homozygosity of the *KIT* gene mutation (individuals III–II, III–III and IV–IV) could derive from the loss of wild type chromosome 4, the location of the wild-type KIT gene and subsequent duplication of the abnormal, rearranged chromosome 4, including the KIT gene with deletion of codon 579 (IV–III).

Imatinib therapy of individuals from a GIST-prone kindred

In the family detailed in our study, 9 of 11 patients not treated with imatinib appear to have died directly and rapidly from metastatic GIST. This is not surprising, because the natural history of metastatic small intestine GIST portends a poor prognosis.[20,21] Conversely, 4 patients who received imatinib therapy are all progression- or recurrence-free for more than 4 years demonstrating a clinical benefit to imatinib therapy.

CT images were reviewed for the proband (IV–IV) and a sibling (IV–III). Individual IV–III was found to have a 1.8-cm nodule in the right upper lobe of the lung anteriorly (Fig. 5*a*). Four months after the initiation of imatinib therapy, a repeat CT demonstrated near complete resolution of the pulmonary nodule (Fig. 5*b*). In addition to multiple intestinal tumors, individual IV–IV was found to have a heterogeneous liver lesion on contrast-enhanced CT (Fig. 5*c*). The patient was initiated on imatinib therapy and at 3-year follow-up CT revealed a minimal change in tumor size but a notable decrease in density within the lesion, which is a CT feature strongly associated with good response (Figs. 5*c* and 5*d*).[22,23] This is the first report to describe *in vivo* radiographic evidence efficacy of imatinib in patients from a GIST prone kindred.

Interpretation

The kindred in this study represents 15 cases of GIST of a total of 79 family members. We describe the clinical presentation, pattern of inheritance, histopathologic appearance of the tumors, clinical or radiographic efficacy of IM therapy and make molecular observations.

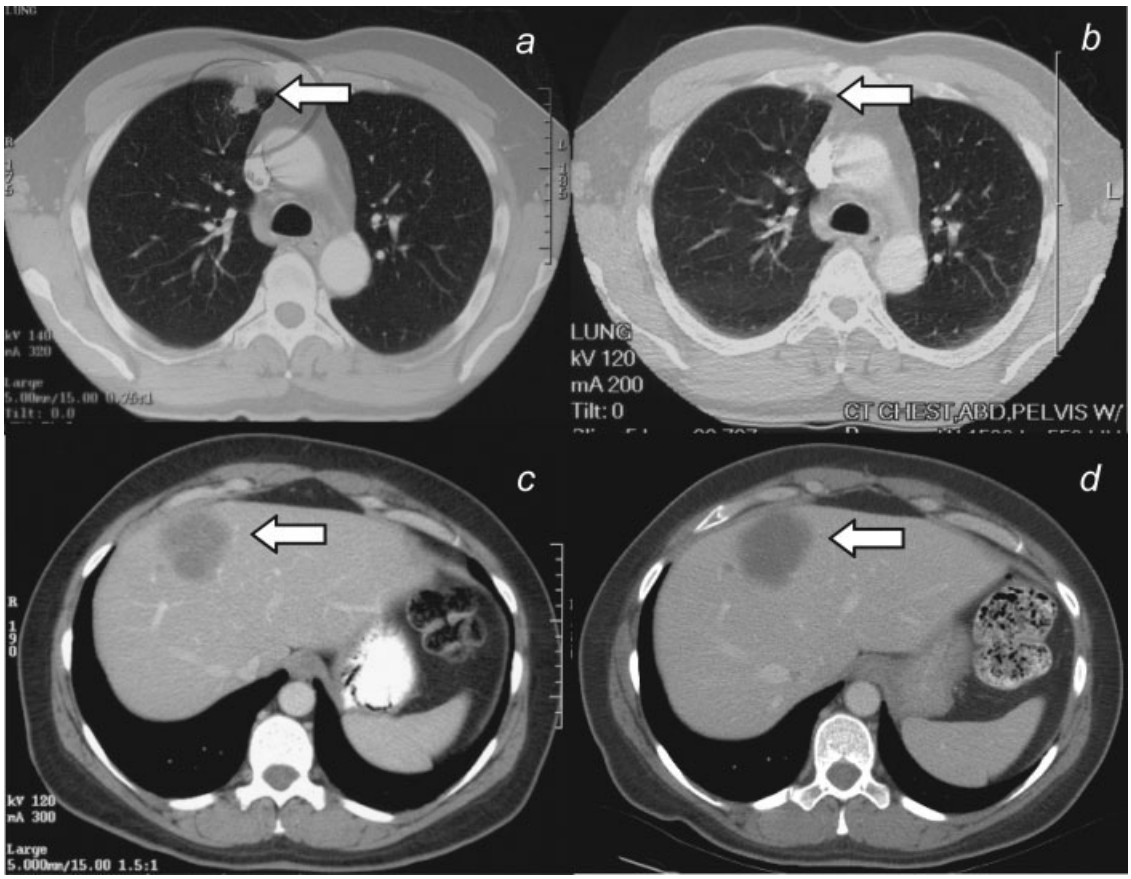

FIGURE 5 – Radiographic findings associated with imatinib therapy of patients from a family with a high propensity of GISTs. (*a*, *b*) Pre- and posttreatment CT scans of chest in patients IV–III. A postoperative contrast-enhanced CT image (*a*) obtained before initiation of imatinib therapy demonstrated one of the pulmonary nodules that subsequently resolved after initiation of imatinib therapy (*b*). (*c*, *d*) Pre- and posttreatment CT scans of abdomen in patients IV–IV. A contrast-enhanced CT image (*c*) obtained before initiation of imatinib therapy demonstrated an enhancing hepatic metastasis with subsequent response on a postimatinib CT image (*d*).

The median age of diagnosis of all kindreds reported in the literature with GIST is 47 years of age,[3–13] notably earlier in onset than that of patients with the sporadic form of the disease where the median age of diagnosis is 60 years.[24,25] The age at diagnosis of GIST in one affected kindred appears to occur earlier in successive generations as noted by Robson *et al*.[12] The mean age of diagnosis in the 4th generation was 34 years of age when compared with 62 years of age in the 2nd generation in that study. Earlier diagnosis in successive generations may be due to improvement in diagnostic technology[26] or genetic variations such as promoter polymophisms.[27] In our study, the median age overall was 53.9 (range 37–71 years), while the most recent generations were diagnosed at a mean age of 55 years (range 45–63 years) compared with the prior generation who were discovered to have GIST at a median age of 54.5 years (range 37–71 years). Thus, we found no apparent trend toward earlier diagnosis of GIST in successive generations as described in the aforementioned study. Although it is possible that earlier age of onset in successive generation is due to the availability of better diagnostic tools, this seems unlikely since CT scans and MRI technology are available to both kindreds. Alternatively, it is possible that a unique genetic variant leads to earlier age of onset in successive generations that is not present or is not apparent in our kindred. Nonetheless, widespread knowledge that the median age of onset is as early as 34 years of age will hopefully lead to earlier diagnosis in GIST-prone kindreds. Although many of the affected patients from the current kindred underwent colonoscopy, this modality did not aid in the diagnosis of a single case. On the other hand, EGD and CT imaging appeared to be useful. Included in the evaluation, genetic screening for mutations in the *KIT* and *PDGFRA* genes should be discussed with these individuals.

The presence of associated conditions in family members is a characteristic of familial GIST as opposed to the sporadic form. Associated manifestations include esophageal dysmotility, hyperpigmentation, urticaria pigmentosa and nevi in kindreds with germ-line mutations in the *KIT* gene. The presence of these manifestations is understandable in view of the role of *KIT* in the development and regulation of the myenteric plexus and melanocytes[28]. The site of mutation within the *KIT* gene may modify the specific clinical manifestations that patients develop as well as the penetrance. In our study, we noted one family member to have hyperpigmentation since childhood that may be associated with the KIT mutation and 2 others had a junctional melanocytic nevus removed. However, no other family members affected by GIST reported any other commonly associated manifestations including cutaneous pigmentation, mastocytomas or esophageal dysmotility. We describe low penetrance skin manifestations to be associated with germ-line deletion of codon 579 but not associated with esophageal dysmotility. Interestingly, 2 members of this kindred were found to have pulmonary lesions. Although not biopsied, the pulmonary lesions were likely GIST in view of the rapid and nearly complete regression after initiation of imatinib therapy (Fig. 4). On the other hand, this family does not meet the criteria of Carney's Triad so it is unlikely to be a pulmonary chondroma.[29] However, we cannot exclude an inflammatory or infectious etiololgy.

In contrast to sporadic gastrointestinal tumors that present with a single primary tumor, surgical intervention performed on an individual with a hereditary GIST may reveal tens to hundreds of tumor nodules.[3,5,7,9–12,30–32] The mitotic rate of the tumors in most of these families (those who were documented) appear to be low suggesting that these tumors appear indolent compared with sporadic GIST.[3,9,10,12,13,30,33] Interestingly, 2 patients in our study presented with metastases at diagnosis despite displaying variable mitotic rates (1 with 5 mitoses per 50 hpf and 1 with 30 mitoses per 50 hpf. As with the sporadic counterpart, the clinical behavior of GIST arising in the kindred can be aggressive even with low mitotic rates.[34] Additionally, patients from a GIST kindred are not only at risk for metastases but also at very high risk for multiple primary tumors. It is our opinion that patients with familial GIST should be categorized as high risk for metastasis irrespective of the size or mitotic rate of the primary tumor. Moreover, our results directly question the applicability of the criteria commonly used to stratify risk of metastasis[35] in the setting of GIST arising in a member of an affected kindred. Furthermore, our observations suggest a need for heightened surveillance in individuals from GIST-prone kindreds.

In GIST kindreds, tumor nodules are often contiguous with areas of hyperplastic ICCs on histopathologic analysis[3,4,9,10,12,30,31,36] suggesting that these tumors arise within the hyperplastic ICC. In our study, the tumor nodules appeared to arise from a background of a hyperplastic Auerbach's plexus in the small bowel (Figs. 2 and 3) consistent with the findings seen in the other reported GIST kindreds. Histologically, it was not possible to draw a clear distinction between hyperplastic myenteric plexi and an early GIST. The presence of a germ-line *KIT* mutation suggests that additional genetic aberrations beyond the seminal *KIT* mutation are required for the transition from hyperplastic enteric plexi to that of a GIST. In our study, the loss of heterozygosity at codon 579 in the tumor cells may have contributed to the genetic events that lead to the development of GIST within the hyperplastic enteric plexus in individual IV–IV. As previously noted, O'Riain described LOH as the potential transforming event resulting in tumorigenesis and a more aggressive phenotype.[13] Additionally, in our experience of *KIT* mutation analysis of over 300 GISTs we have observed loss of heterozygosity as a rare occurrence in sporadic GISTs (data not shown). This finding suggests that this loss of heterozygosity may provide a proliferative or survival advantage compared with areas within the myenteric plexus that have retained a wild-type *KIT* gene. Thus, *KIT* oncogene "dose" may correlate with tumorigenicity but clearly does not appear to result in IM resistance (Figs. 5*a* and 5*b*) since our patient with LOH remained sensitive to IM. If LOH represents the transforming event it is interesting to speculate whether IM may be able to reverse the hyperproliferation of the myenteric plexus and actively prevent the accumulation of additional genetic events and subsequent tumor formation.

Site of primary GIST and *KIT* mutation site have been described as important prognostic factors in GIST. Interestingly, GIST kindreds reported to date have been described to have primary GISTs arise from the small intestine[3,9,10,12,13,31,32,37,38] or the small intestine and the stomach[12,13,30,36,39] but not the stomach alone. On the other hand, studies have demonstrated that nearly two-thirds of all sporadic GISTs arise in the stomach. Tumor-associated mortality was significantly higher in the patients with their primary GIST arising in the small intestine when compared with the stomach (35 *vs.* 18%).[21,40,41] In a large study of over 100 sporadic GISTs, the most sensitive mutation to IM therapy was exon 11 (83.5% response rate) followed by exon 9 (47.8% response rate) and that patients with exon 11 mutations had longer overall survival on imatinib therapy.[42] However, it remains unclear as to whether the site of mutation in the *KIT* gene or the site of the primary GIST is the most important predictor of response to IM therapy in the setting of germ-line *KIT* mutation. While our proband has only received the therapy for 3 years, patients III–II, III–III and IV–III have had complete or partial responses while receiving medical therapy with IM for greater than 4 years. This is somewhat surprising because all of the affected patients in our study had multifocal or metastatic small intestine GIST as opposed to gastric GIST. All 4 of the patients within this kindred with metastatic or multifocal GISTs are alive and progression-free on IM. This observation along with the radiographic response of 2 patients to IM (Fig. 4) confirm the IM-sensitivity of both the heterozygous and homozygous mutant familial genotype, a unique observation.

In conclusion, we report a kindred with an autosomal dominant pattern of GIST formation that appears to be due to a germ-line 3 base-pair deletion at codon 579 in exon 11 of the *KIT* gene. One tumor (in patient IV–III) was found to encode loss of the wild type allele with the retention of the locus carrying the germ-line *KIT* mutation. This mutation is associated with an onset at a mean age of 53.9 years, low mitotic rate in the setting of metastases, clinical benefit from imatinib therapy and an individual with loss of the wild type *KIT* gene. However, many questions remain to be answered in the study of GIST-prone kindreds. These questions vary from the natural history of the disease when compared with sporadic GIST to when the appropriate time to screen patients in kindreds with GIST. The discovery and reporting of more families with hereditary GIST will allow an estimate of its incidence and prevalence. Moreover, the continued advancement in the understanding of the pathophysiology of GIST in familial syndromes will direct the management of this subset of patients.

References

1. Huizinga JD, Faussone-Pellegrini MS. About the presence of interstitial cells of Cajal outside the musculature of the gastrointestinal tract. J Cell Mol Med 2005;9:468–73.
2. Corless CL, Fletcher JA, Heinrich MC. Biology of gastrointestinal stromal tumors. J Clin Oncol 2004;22:3813–25.
3. Handra-Luca A, Flejou JF, Sauvanet A, Belghiti J, Degott C, Terris B. Familial multiple gastrointestinal stromal tumours with associated abnormalities of the myenteric plexus layer and skenoid fibres. Histopathology 2001;39:359–63.
4. Baselga J, Arteaga CL. Critical update and emerging trends in epidermal growth factor receptor targeting in cancer. J Clin Oncol 2005; 23:2445–59.
5. Chompret A, Kannengeisser C, Barrois M, Terrier P, Dahan P, Tursz T, Lenoir GM, Bressac-De Paillerets B. *PDGFRA* germline mutation in a family with multiple cases of gastrointestinal stromal tumor. Gastroenterology 2004;126:318–21.
6. Maeyama H, Hidaka E, Ota H, Minami S, Kajiyama M, Kuraishi A, Mori H, Matsuda Y, Wada S, Sodeyama H, Nakata S, Kawamura N, et al. Familial gastrointestinal stromal tumor with hyperpigmentation: association with a germline mutation of the c-kit gene. Gastroenterology 2001;120:210–15.
7. Chen H, Hirota S, Isozaki K, Sun H, Ohashi A, Kinoshita K, O'Brien P, Kapusta L, Dardick I, Obayashi T, Okazaki T, Shinomura Y, et al. Polyclonal nature of diffuse proliferation of interstitial cells of Cajal in patients with famililial and multiple gastrointestinal stromal tumours. Gut 2002;51:793–6.
8. Hirota S, Okazaki T, Kitamura Y. Cause of familial and multiple gastrointestinal autonomic nerve tumors with hyperplasia of the interstitial cells of Cajal is a germline mutation of the c-kit gene. Am J Surg Pathol 2000;24:326–7.
9. O'Brien P, Kapusta L, Dardick I, Axler J, Gnidec A. Multiple familial gastrointestinal autonomic nerve tumors and small intestinal neuronal dysplasia. Am J Surg Pathol 1999;23:198–204.
10. Isozaki K, Terris B, Belghiti J, Schiffmann S, Hirota S, Vanderwinden JM. Germline-activating mutation in the kinase domain of KIT gene in familial gastrointestinal stromal tumors. Am J Pathol 2000; 157: 1581–5.
11. Hirota S, Isozaki K, Moriyama Y, Hashimoto K, Nishida T, Ishiguro S, Kawano K, Hanada M, Kurata A, Takeda M, Muhammad TG, Matsuzawa Y, et al. Gain-of-function mutations of c-kit in human gastrointestinal stromal tumors. Science 1998;279:577–80.

12. Robson ME, Glogowski E, Sommer G, Antonescu CR, Nafa K, Maki RG, Ellis N, Besmer P, Brennan M, Offit K. Pleomorphic characteristics of a germ-line KIT mutation in a large kindred with gastrointestinal stromal tumors, hyperpigmentation and dysphagia. Clin Cancer Res 2004;10:1250–4.
13. O'Riain C, Corless C, Heinrich M, Keegan D, Vioreanu M, Maguire D, Sheahan K. Gastrointestinal stromal tumors: insights from a new familial GIST kindred with unusual genetic and pathological features. Am J Surg Pathol 2005;29:1680–83.
14. Blay JY, Bonvalot S, Casali P, Choi H, Debiec-Richter M, Dei Tos AP, Emile JF, Gronchi A, Hogendoom PC, Joensuu H, LeCesne A, McClure J, et al. Consensus meeting for the management of gastrointestinal stromal tumors: report of the GIST consensus conference 20–21 March 2004, under the auspices of ESMO. Ann Oncol 2005;16: 566–78.
15. Chen LL, Trent JC, Wu EF, Fuller GN, Ramdas L, Zhang W, Raymond AK, Prieto VG, Oyedeji CO, Hunt KK, Pollock RE, Feig BW, et al. A missense mutation in KIT kinase domain 1 correlates with imatinib resistance in gastrointestinal stromal tumors. Cancer Res 2004;64:5913–9.
16. Lagonigro MS, Tamborini E, Negri T, Staurengo S, Dagrada GP, Miselli F, Gabanti E, Greco A, Casali PG, Carbone A, Pierotti MA, Pilotti S. *PDGFRa*lpha, PDGFRbeta and KIT expression/activation in conventional chondrosarcoma. J Pathol 2006;208:615–23.
17. Chung CH, Ely K, McGavran L, Varella-Garcia M, Parker J, Parker N, Jarrett C, Carter J, Murphy BA, Netterville J, Burkey BB, Sinard R, et al. Increased epidermal growth factor receptor gene copy number is associated with poor prognosis in head and neck squamous cell carcinomas. J Clin Oncol 2006;24:4170–6.
18. Hirsch FR, Varella-Garcia M, McCoy J, West H, Xavier AC, Gumerlock P, Bunn PA, Jr, Franklin WA, Crowley J, Gandara DR; Southwest Oncology Group. Increased epidermal growth factor receptor gene copy number detected by fluorescence in situ hybridization associates with increased sensitivity to gefitinib in patients with bronchioloalveolar carcinoma subtypes: a Southwest Oncology Group Study [see comment]. J Clin Oncol 2005;23:6838–45.
19. Rubin BP, Antonescu CR, Scott-Browne JP, Comstock ML, Gu Y, Tanas MR, Ware CB, Woodell J. A knock-in mouse model of gastrointestinal stromal tumor harboring kit K641E. Cancer Res 2005;65: 6631–9.
20. Miettinen M, Sobin LH, Lasota J. Gastrointestinal stromal tumors of the stomach: a clinicopathological, immunohistochemical, and molecular genetic study of 1765 cases with long-term follow-up. Am J Surg Pathol 2005;29:52–68.
21. Miettinen M, Kopczynski J, Makhlouf HR, Sarlomo-Rikala M, Gyorffy H, Burke A, Sobin LH, Lasota J. Gastrointestinal stromal tumors, intramural leiomyomas, and leiomyosarcomas in the duodenum: a clinicopathologic, immunohistochemical, and molecular genetic study of 167 cases. Am J Surg Pathol 2003;27:625–41.
22. Choi H, Charnsangavej C, de Castro Faria S, Tamm EP, Benjamin RS, Johnson MM, Macapinlac HA, Podoloff DA. CT evaluation of the response of gastrointestinal stromal tumors after imatinib mesylate treatment: a quantitative analysis correlated with FDG PET findings [see comment]. AJR Am J Roentgenol 2004;183:1619–28.
23. Hong X, Choi H, Loyer EM, Benjamin RS, Trent JC, Charnsangavej C. Gastrointestinal stromal tumor: role of CT in diagnosis and in response evaluation and surveillance after treatment with imatinib. Radiographics 2006;26:481–95.
24. DeMatteo RP, Lewis JJ, Leung D, Mudan SS, Woodruff JM, Brennan MF. Two hundred gastrointestinal stromal tumors: recurrence patterns and prognostic factors for survival. Ann Surg 2000;231:51–8.
25. Ng EH, Pollock RE, Romsdahl MM. Prognostic implications of patterns of failure for gastrointestinal leiomyosarcomas. Cancer 1992; 69:1334–41.
26. Hemminki K, Bermejo JL. Effects of screening for breast cancer on its age-incidence relationships and familial risk. Int J Cancer 2005; 117:145–9.
27. Jones JS, Amos CI, Pande M, Gu X, Chen J, Campos IM, Wei Q, Rodriguez-Bigas M, Lynch PM, Frazier ML. DNMT3b polymorphism and hereditary nonpolyposis colorectal cancer age of onset. Cancer Epidemiol Biomarkers Prev 2006;15:886–91.
28. Nocka K, Majumder S, Chabot B, Ray P, Cervone M, Bernstein A, Besmer P. Expression of c-kit gene products in known cellular targets of W mutations in normal and W mutant mice—evidence for an impaired c-kit kinase in mutant mice. Genes Dev 1989;3:816–26.
29. Carney JA. Gastric stromal sarcoma, pulmonary chondroma, and extra-adrenal paraganglioma (Carney Triad): natural history, adrenocortical component, and possible familial occurrence [see comments.]. Mayo Clin Proc 1999;74:543–52.
30. Beghini A, Tibiletti M, Roversi G, Chiavaralli AM, Serio G, Capella C, Larizza L. Germline mutation in the juxtamembraine domain of the kit gene in a family with gastrointestinal stromal tumors and urticaria pigmentosa. Cancer 2001;92:657–62.
31. Hartmann K, Wardelmann E, Yongsheng M, Merkelbach-Bruse S, Pruessner LM, Woolery C, Baldus SE, Heinicke T, Thiele J, Buettner R, Longley BJ. Novel germline mutation of KIT associated with familial gastrointestinal stromal tumor and mastocytosis. Gastroenterology 2005;129:1042–6.
32. Li F, Fletcher JA, Heinrich MC, Garber JE, Sallan SE, Curiel-Lewandrowski C, Duensing A, van de Rijn M, Schnipper LE, Demetri GD. Familial gastrointestinal stromal tumor syndrome: phenotypic and molecular features in a kindred. J Clin Oncol 2005;23: 2735–43.
33. Nishida T, Hirota S, Taniguchi M, Hashimoto K, Isozaki K, Nakamura H, Kanakura Y, Tanaka T, Takabayashi A, Matsuda H, Kitamura Y. Familial gastrointestinal stromal tumours with germline mutation of the KIT gene. Nature Genet 1998;19:323–4.
34. Nowain A, Bhakta H, Pais S, Kanel G, Verma S. Gastrointestinal stromal tumors: clinical profile, pathogenesis, treatment strategies and prognosis. J Gastroenterol Hepatol 2005;20:818–24.
35. Nilsson B, Bèumming P, Meis-Kindblom JM, Odâen A, Dortok A, Gustavsson B, Sablinska K, Kindblom LG. Gastrointestinal stromal tumors: the incidence, prevalence, clinical course, and prognostication in the preimatinib mesylate era—a population-based study in western Sweden. Cancer 2005;103:821–9.
36. Carballo M, Roig I, Aguilar F, Pol MA, Gamundi MJ, Hernan I, Martinez-Gimeno M. Novel c-kit germline mutation in a family with gastrointestinal stromal tumors and cutaneous hyperpigmentation. Am J Med Genet 2005;132:361–64.
37. Marshall JB, Diaz-Arias AA, Bochna GA, Vogele KA. Achalasia due to diifuse esophageal leiomyomatosis and inherited as an autosomal dominant disorder. Gastroenterology 1990;98:1358–65.
38. Chen Y, Tzeng CC, Liou CP, Chang MY, Li CF, Lin CN. Biological significance of chromosomal imbalance aberrations in gastrointestinal stromal tumors. J Biomed Sci 2004;11:65–71.
39. Hirota S, Nishida T, Isozaki K, Taniguchi M, Nishikawa K, Ohashi A, Takabayashi A, Obayashi T, Okuno T, Kinoshita K, Chen H, Shinomura Y, et al. Familial gastrointestinal stromal tumors associated with dysphagia and novel type germline mutation of KIT gene. Gastroenterology 2002;122:1493–9.
40. Miettinen M, Sobin LH, Lasota J. Gastrointestinal stromal tumors of the stomach: a clinicopathologic, immunohistochemical, and molecular genetic study of 1765 cases with long-term follow-up. Am J Surg Pathol 2005;29:52–68.
41. Emory T, Sobin LH, Lukes L, Lee D, O'Leary TJ. Prognosis of gastrointestinal smooth muscle (stromal) tumors: dependence on anatomic site. Am J Surg Pathol 1999;23:82–7.
42. Heinrich MC, Corless C, Demetri GD, Blanke CD, von Mehren M, Joensuu H, McGreevey LS, Chen CJ, van de Abbeele AD, Druker BJ, Kiese B, Eisenberg B, et al. Kinase mutations and imatinib response in patients with metastatic gastrointestinal stromal tumor. J Clin Oncol 2003;21:4342–49.