Correlation of Immunophenotype With Progression-Free Survival in Patients With Gastrointestinal Stromal Tumors Treated With Imatinib Mesylate

Lucian R. Chirieac, MD[1]
Jonathan C. Trent, MD, PhD[2]
Dejka M. Steinert, MD[2]
Haesun Choi, MD[3]
Ying Yang, PhD[4]
Jiexin Zhang, MS[4]
Shreyaskumar R. Patel, MD[2]
Robert S. Benjamin, MD[2]
A. Kevin Raymond, MD[1]

[1] Department of Pathology, The University of Texas M. D. Anderson Cancer Center, Houston, Texas.

[2] Department of Sarcoma Medical Oncology, The University of Texas M. D. Anderson Cancer Center, Houston, Texas.

[3] Department of Diagnostic Radiology, The University of Texas M. D. Anderson Cancer Center, Houston, Texas.

[4] Department of Biostatistics and Applied Mathematics, The University of Texas M. D. Anderson Cancer Center, Houston, Texas.

Supported by an institutional Physician-Scientist Award (to J.C.T.) and a National Institutes of Health/National Cancer Institute grant (1K23CA109060-01) (to J.C.T.).

Lucian R. Chirieac's current address: Department of Pathology, Brigham and Women's Hospital, Harvard Medical School, Boston, Massachusetts.

Address for reprints: A. Kevin Raymond, MD, Department of Pathology, Unit 085, The University of Texas M. D. Anderson Cancer Center, 1515 Holcombe Boulevard, Houston, TX 77030; Fax: (713) 745-8610; E-mail: kraymond@rndanderson.org

Address for reprints: Jonathan C. Trent, MD, PhD, Department of Sarcoma Medical Oncology, Unit 450, The University of Texas M. D. Anderson Cancer Center, 1515 Holcombe Boulevard, Houston, TX 77030; Fax: (713) 794-1934; E-mail: jtrent@mdanderson.org

Received June 27, 2006; revision received July 27, 2006; accepted July 27, 2006.

BACKGROUND. The therapy for gastrointestinal stromal tumor (GIST) has been revolutionized by imatinib mesylate (IM). It is unknown whether the levels of KIT expression or the presence of CD34, smooth muscle actin (SMA), desmin, or S-100 protein predicts patient outcome from IM therapy. In the current study, the prognostic effects for KIT and other proteins (CD34, SMA, desmin, S-100) were analyzed in a series of GISTs in which protein expression was evaluated by immunohistochemical analysis (IHC).

METHODS. The cases of 106 patients with GIST who were uniformly treated with IM at the study institution between December 15, 2000, and January 13, 2002 were evaluated retrospectively. The association between KIT intensity, CD34, desmin, SMA, S-100 protein, and progression-free survival (PFS) was studied. Kaplan-Meier analysis and the Cox proportional hazards regression model were used for statistical analysis.

RESULTS. The majority of tumors arose from the stomach (37%), small intestine (35%), and colorectum (14%). KIT expression as determined by IHC was categorized as weak (10%), intermediate (32%), or strong (58%). Patient tumors expressed CD34 (75%), SMA (56%), desmin (1%), and S-100 protein (32%). Patients whose GIST had weak, intermediate, or strong KIT expression were found to have an 18-month PFS rate of 80%, 84%, and 69%, respectively ($P = .30$). The presence or absence of CD34, SMA, desmin, or S-100 protein did not appear to correlate with PFS after IM.

CONCLUSIONS. Patients with the appropriate clinical presentation and KIT-positive GIST tumors appear to benefit from IM independent of the level of KIT or the expression of CD34, SMA, desmin, or S-100 protein by IHC. ***Cancer* 2006;107: 2237–44.** © *2006 American Cancer Society.*

KEYWORDS: gastrointestinal stromal tumor, imatinib mesylate, immunohistochemistry, outcome.

Gastrointestinal stromal tumors (GISTs) are the most common mesenchymal tumors of the gastrointestinal tract. Approximately 4000 new cases are diagnosed every year in the U.S.[1] The median age at diagnosis is 58 years.[2] GISTs account for approximately 2% of all stomach cancers, 14% of all small intestine tumors, and 0.1% of colon cancers.

Although surgery is often an effective therapy for patients with a primary GIST, patients with advanced GISTs do not benefit from cytotoxic chemotherapy.[3,4] Imatinib mesylate (IM; Gleevec, Glivec, formerly STI571; Novartis Pharmaceuticals, Hanover, NJ), a selective inhibitor of certain protein tyrosine kinases: the intracellular ABL kinase, the chimeric BCR-ABL fusion oncoprotein of chronic myeloid leukemia, the transmembrane receptor KIT, and the platelet-derived growth factor receptors (PDGFR); has been markedly active in the treatment of patients with advanced GIST. In clinical trials, patients

© 2006 American Cancer Society
DOI 10.1002/cncr.22226
Published online 22 September 2006 in Wiley InterScience (www.interscience.wiley.com).

with GIST in advanced stages treated with IM have a high response rate and higher survival rates compared with historical controls.[5–9]

Immunohistochemical staining for KIT, CD34, smooth muscle actin (SMA), desmin, and S-100 protein has been recommended to aid in the diagnosis of GIST.[10] Expression of the KIT receptor tyrosine kinase (stem cell factor receptor, CD117) is common in GIST as shown by immunohistochemical analysis.[10–12] Most GISTs that express the KIT oncoprotein also have an activating mutation in the *kit* gene.[13–17] A small subset of GISTs do not express detectable KIT protein yet have activating mutations in the *kit* or *PDGFR*-α genes.[18] In GIST patients treated with IM, the relevance of KIT expression level to clinical benefit from IM is to our knowledge unknown.

GISTs demonstrate variants based on the intensity of immunohistochemical expression of KIT and the presence or absence of CD34, SMA, desmin, and S-100 protein. The level of expression of the KIT protein may translate into differences in tumor aggressiveness and influence the likelihood of a clinical response to IM. Preliminary observations linked clinical benefit to the presence of KIT mutations in the tumor.[19,20] Moreover, patients whose tumor encoded exon 11 mutations had a greater median progression-free survival (PFS) than patients whose GIST encoded exon 9 mutations or those with wild-type *kit*.[21]

The purpose of this study was to evaluate the prevalence and the prognostic implications of KIT expression intensity by immunohistochemistry in patients with GIST treated with IM. In addition, we evaluated the expression of CD34, SMA, desmin, and S-100 protein and correlated the findings with PFS. In this study we present the results of a clinicopathologic analysis in patients with GIST treated at the University of Texas M. D. Anderson Cancer Center.

TABLE 1
Summary of Patient Characteristics

Characteristic	No. (%)* of evaluable patients (n = 106)
Gender	
Male	53 (50.0)
Female	53 (50.0)
Age, y	
Median	55
Range	25–86
Mitoses, no. per 10 HPF	
Average	7.8
Range	0–50
Tumor size, cm	
Median	11.7
Range	2.7–35
ECOG status	
0–2	102 (96.2)
3	4 (3.9)
Site of tumor at diagnosis	
Stomach	39 (36.8)
Small bowel	37 (34.7)
Colorectum	15 (14.1)
Mesentery and omentum	5 (4.7)
Esophagus	2 (1.8)
Rectovaginal	2 (1.8)
Other	8 (7.5)
Site of tumor at recurrence	
Any recurrent disease	102 (96.2)
Liver	87 (82.1)
Peritoneal	60 (56.6)
Lung	6 (5.6)
Lymph nodes	3 (2.8)
Previous treatment	
Surgery	67 (63.2)
Chemotherapy	2 (1.9)
Surgery and chemotherapy	34 (32.0)
None	3 (2.8)

HPF indicates high-power fields; ECOG, Eastern Cooperative Oncology Group.
* Because of rounding, not all percentages equal 100.

MATERIALS AND METHODS

Patients

One hundred six consecutive patients with histologically confirmed GIST treated with IM at the University of Texas M. D. Anderson Cancer Center in Houston, Texas between December 15, 2000 and January 13, 2002 were evaluated (Table 1). Clinical data obtained included age, gender, dose of IM, primary tumor site of origin, and date of disease progression. All data were coded with patient identifiers. The study was approved by the Institutional Review Board and a waiver of informed consent was obtained.

Histopathologic Evaluation

Formalin-fixed, paraffin-embedded pathology specimens were retrieved from the files of the Pathology Department and cut into 5-μm thick serial sections. The study group included patients whose primary tumors originated from the gastrointestinal tract, were typical of GIST by histologic morphology, and expressed KIT by immunohistochemistry. Tumor was sampled for histologic evaluation in an average of 14 slides (range, 5–38 slides). Immunohistochemistry and hematoxylin and eosin (H & E) staining were performed. Microscopic examination as well as protein expression was scored independently by 2 pathologists (L.R.C. and A.K.R.) without knowledge of the therapy regimen or outcome. The area of each microscopic field was 0.391 mm^2. Each specimen was evaluated for the number of mitoses according to published recommendations.[10,22]

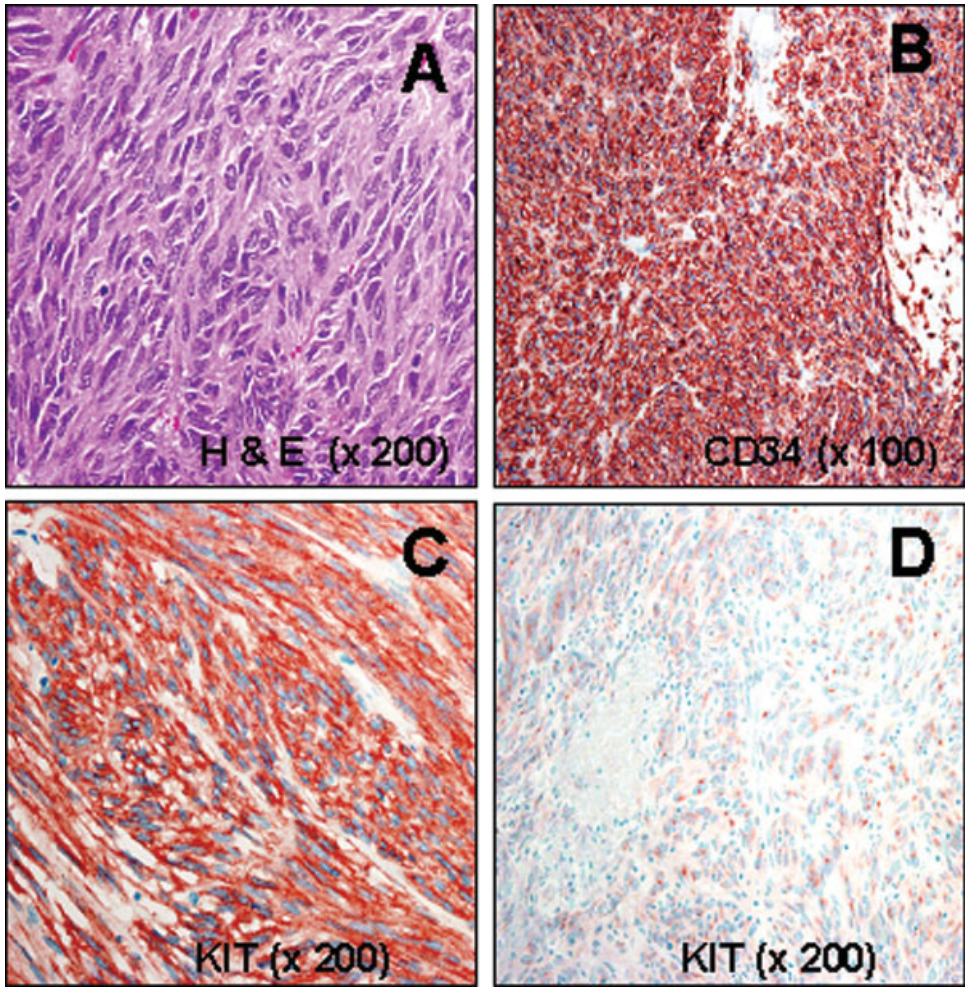

FIGURE 1. Photomicrographs illustrating gastrointestinal stromal tumors (GISTs). (A) Hematoxylin and eosin (H & E) staining. (B) Seventy-six percent of the evaluated tumors expressed CD34. (C, D) KIT expression of 2 tumors from different patients were evaluated (Panel C illustrates a GIST with strong KIT immunoreactivity, whereas the tumor illustrated in Panel D has weak KIT immunoreactivity).

Immunohistochemistry was performed by the avidin-biotin-peroxidase complex method, using antibodies against KIT (polyclonal, CD1M; Dako Corporation, Carpinteria, CA), CD34 (monoclonal, HPCA-1, My10; Becton Dickinson, San Jose, CA), desmin (monoclonal, D33; Dako Corporation), SMA (monoclonal, IA4, Sigma Chemical Company, St. Louis, MO), and S-100 protein (polyclonal, 15EZEZ; Ventana, Tucson, AZ). Tissue samples were classified according to the level of KIT expression. In each specimen, 1000 tumor cells were examined. The staining intensity of KIT immunoreactive cells was subjectively evaluated to have the following degrees of immunoreactivity: weak (+), intermediate (++), or strong (+++) using the intensity of mast cells (internal and external controls) as a reference (score 3+). The immunoreactivity for CD34, desmin, SMA, and S-100 protein was evaluated as positive or negative. Appropriate negative and positive controls were included.

Statistical Analysis

PFS was computed from the time of treatment with IM to the date of progression of disease, date of death, or the last follow-up date. Patients who died from causes other than progression of disease were censored. Survival was estimated using the Kaplan-Meier product-limit method.[23] The 2-sided log-rank test was used to test the association between patient variables and survival. Multivariate analysis was performed using a Cox proportional hazards regression model to determine the association between KIT and survival, after adjusting for the role of other factors.[24] All *P*-values presented are 2-sided, and a *P*-value $<.05$ was considered

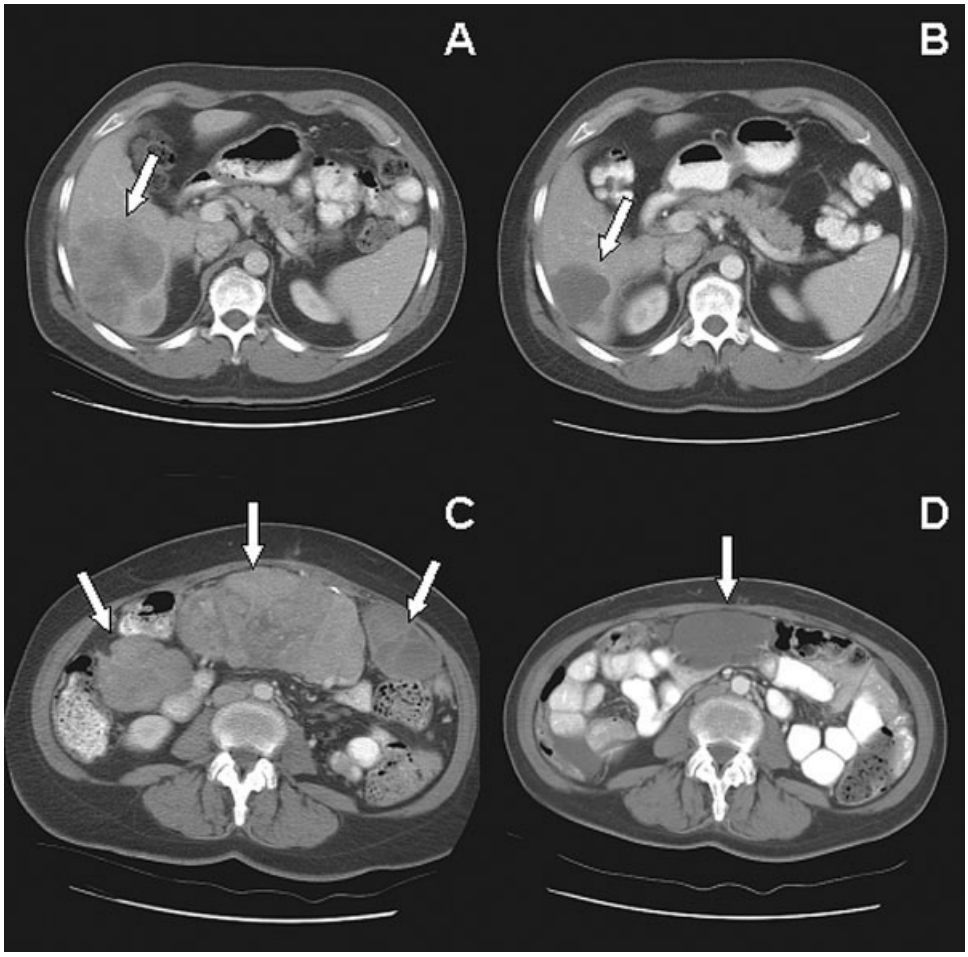

FIGURE 2. Radiographic effects of imatinib mesylate (IM) therapy in patients with gastrointestinal stromal tumors (GISTs) demonstrating low KIT expression. (A, B) A patient with a large liver metastasis found to have low KIT expression responded to IM therapy, as evidenced by a decrease in tumor size and density as assessed by computed tomography (CT). (C, D) A patient with multiple, low KIT-expressing, intraperitoneal GISTs was found to have significant tumor shrinkage and a decrease in tumor density on CT.

statistically significant. Statistical analyses were performed using S-plus software (version 6; Insightful, Seattle, WA).

RESULTS

Patient Demographics and Histopathologic Characteristics

The demographics and histopathologic characteristics of the patients with GIST are summarized in Table 1. All patients had GIST with the appropriate histologic appearance by H & E staining (Fig. 1A). There were 53 men and 53 women. The median age was 55 years (range, 25–86 years). Most of the primary tumors were in the stomach (n = 39 patients [37%]) and small bowel (n = 37 patients [35%]). The remainder of the evaluated cases were located in less common sites such as the colon or rectum (n = 15 patients [14%]), mesentery or omentum (n = 5 patients [5%]), esophagus (n = 2 patients [2%]), and the rectovaginal pouch (n = 2 patients [2%]). Most patients had liver metastases (n = 87 patients [82%]) or intraperitoneal sarcomatosis (n = 60 patients [57%]), although lung or lymph node metastases were less common. The median tumor size was 11.7 cm (range, 2.7–35 cm) and the tumor mitotic index ranged from 0 to 50 mitoses per 10 high-power fields (average 7.8 mitoses per 10 high-power fields). All tumors had the histopathologic features of GIST and were found to express KIT by immunohistochemistry (Fig. 2C and 2D). Two patients (2%) had prior treatment with chemotherapy alone, 67 patients (63%) had prior surgery alone, and 34 patients (32%) were previously treated with both surgery and chemotherapy. Three patients (3%) had IM as their first therapy.

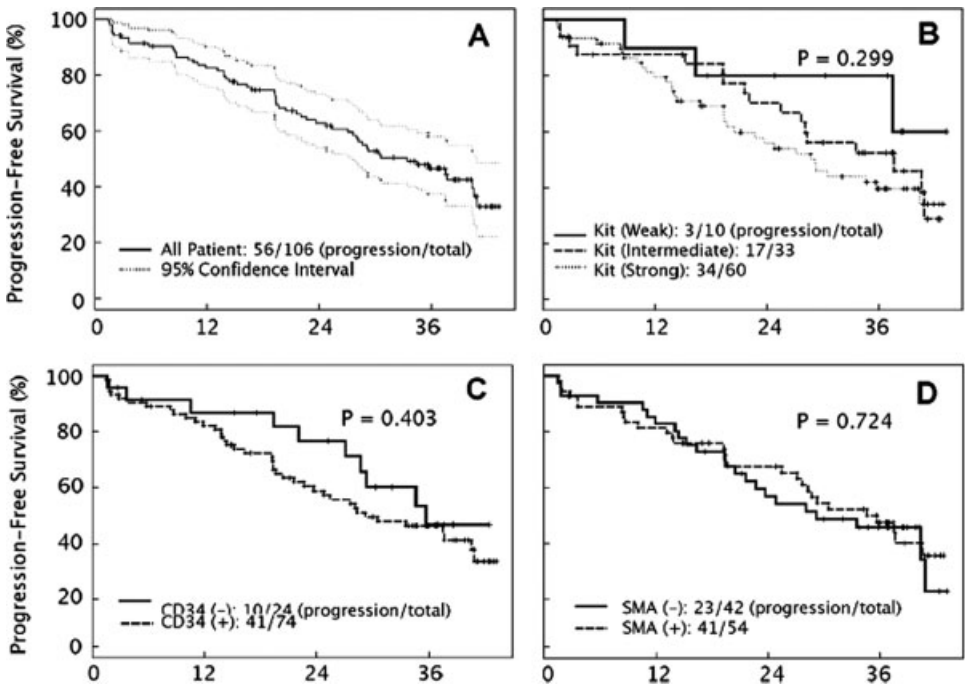

FIGURE 3. Kaplan-Meier estimates of progression-free survival (PFS) among patients with gastrointestinal stromal tumors (GISTs) who were treated with imatinib mesylate (IM). (A) The median PFS of all patients with KIT-expressing GIST. (B) There was a trend toward a superior 2-year PFS in patients whose tumors demonstrated low KIT expression compared with those with strong KIT expression ($P = .12$). (C and D) In contrast, there was no difference noted with regard to the 2-year PFS between patients with the presence or absence of (C) CD34 or (D) smooth muscle actin. − indicates absence; + indicates presence.

GIST Immunophenotype

Immunostaining for KIT protein was available for review in 103 of the 106 cases (97%). For some tumors there was insufficient cellularity on the recut paraffin sections for satisfactory immunohistochemical analysis of ≥1 markers. Ten of the 103 tumor samples (10%) demonstrated minimal KIT expression by immunohistochemistry and were classified as having weak expression (Fig. 1D). Thirty-three tumors (32%) had intermediate KIT expression and 60 tumors (58%) had strong KIT expression that was comparable to that of the mast cell internal control (Fig. 1C). Ninety-eight tumors were technically satisfactory for evaluation of anti-CD34 and desmin staining; 96 tumors were satisfactory for evaluation of SMA expression; and staining with anti-S-100 protein could be evaluated in 92 cases. The majority of tumors expressed CD34 (76%) (Fig. 1B) and SMA (56%). As expected, few tumors expressed desmin (1%) or S-100 protein (32%). Although the clinical significance is not apparent from published data, a proportion of patients that had KIT-positive advanced GIST were found to express KIT at low levels as detected by immunohistochemistry (Fig. 1D).

Radiographic Effects of IM on GISTs with Weak KIT Intensity

We next sought to determine whether the patients whose tumors displayed weak KIT expression benefited from IM therapy. Patients with GIST were evaluated and found to have the histopathologic features typical of GIST, although KIT intensity was weak by immunohistochemistry (Fig. 1D). These patients had similar clinicopathologic characteristics as those of the entire study population.

Impact of Immunophenotype on PFS in Patients with GIST Treated with IM

The median PFS of all patients with KIT-expressing GIST in this study was similar to that observed in other studies (Fig. 3A). At the time of our analysis, the median follow-up time was 36.9 months. Univariate Cox regression analysis showed that expression of KIT, CD34, desmin, SMA, and S-100 protein were not prognostic indicators for disease-free survival (Table 2). Moreover, KIT intensity was not a prognostic indicator of PFS ($P = .30$). Although not significant, the median PFS rate was better among patients with GIST having weak KIT expression (median PFS not reached) than it

TABLE 2
Association of Markers with Progression-Free Survival

	No. of evaluable patients (%)*	Median PFS, months	P†
KIT intensity‡			.30
Weak	10 (10)	NR	
Intermediate	33 (32)	38	
Strong	60 (58)	29	
CD34 expression			.40
No	24 (24)	36	
Yes	74 (75)	29	
SMA expression			.72
No	42 (44)	29	
Yes	54 (56)	35	
Desmin expression			.29
No	97 (99)	35	
Yes	1 (1)	NA	
S-100 expression			.50
No	63 (68)	29	
Yes	29 (32)	38	

PFS indicates progression-free survival; NR, not recorded; SMA, smooth muscle actin; NA, not available.
* Because of rounding, not all percentages total 100. Data were not available for some of the patients.
† *P* was derived from the log-rank test.
‡ Cochran-Armitage test for trend.

TABLE 3
Results of Multivariate Cox Regression Analysis of Progression-Free Survival

Variable	No. of evaluable patients (%) (*n* = 106)* †	Progression-free survival HR	(95% CI)	P
KIT intensity				
Weak (reference)	10 (10)	1.00		
Intermediate	33 (32)	2.84	(0.38–21.45)	.31
Strong	60 (58)	4.33	(0.59–31.84)	.15
CD34 expression				.39
No (reference)	24 (24)	1		
Yes	74 (75)	1.42	(0.64–3.19)	
Desmin expression				.23
No (reference)	97 (99)	1		
Yes	1 (1)	NA	NA	
SMA expression				.46
No	42 (44)	1		
Yes	54 (56)	0.79	(0.43–1.47)	
S-100 expression				.32
No	63 (68)	1.00		
Yes	29 (32)	0.71	(0.37–1.39)	

HR indicates hazards ratio; 95% CI, 95% confidence interval; NA, not available; SMA, smooth muscle actin.
* Data were not available for some of the patients.
† Because of rounding, not all percentages total 100.

was among patients GIST having moderate KIT expression (38 months), or strong expression (29 months) ($P = .30$) (Fig. 3B). The PFS did not differ significantly between patients with CD34-positive GIST and patients with CD34-negative GIST (36 months vs. 29 months; $P = .40$) (Fig. 3C). In addition, expression of SMA (Fig. 3D) or S-100 protein (data not shown) by tumor cells in GISTs from patients treated with IM was found to have no significant effect on the PFS. There were too few patients with desmin-expressing GIST to correlate with PFS (Table 3).

A Cox proportional hazards model was fitted using data for all patients to assess the joint associations between KIT and other markers with PFS. After adjusting for significant variables, we found that there was a trend such that the 18-month PFS was worse for patients whose tumors exhibited strong KIT expression compared with those patients whose tumors had weak or intermediate KIT expression ($P = .10$). When patients with metastatic GIST were treated with IM, the PFS was found to be similar for all patients when evaluated by CD34, S-100 protein, and SMA expression in our model (Table 3).

DISCUSSION

GISTs show immunophenotypic variants based on levels of KIT expression that have unknown clinical significance.[10,25] In the current study, we investigated whether there is a difference in benefit from IM therapy in GIST patients with different levels of KIT expression. We evaluated 106 patients with histologically confirmed GISTs who were treated with IM at the University of Texas M. D. Anderson Cancer Center between 2000 and 2002. We performed immunohistochemical analyses and evaluated clinical outcomes to determine whether the presence of KIT, CD34, SMA, desmin, or S-100 protein predicts the clinical benefit that patients with GIST obtain when treated with IM. We also categorized GISTs according to the levels of KIT expression by immunohistochemistry and correlated the data with PFS. Previous reports show that 60% to 80% of GISTs are immunohistochemically positive for CD34 and sometimes positive for actin, but rarely are positive for desmin or S-100 protein.[26] The presence of these proteins may signify biologic differences in tumor aggressiveness and influence the likelihood of a clinical benefit from IM.

We describe GIST patients whose tumors had low KIT expression benefiting from IM therapy. Patients have been treated with different doses and intensities, and one might hypothesize that these parameters have a significant impact on patient outcome, although their relative importance is an area of great interest and debate.[9,27,28] Either a decrease in tumor size or a decrease in tumor density provides an objective

assessment of GIST response to IM therapy.[29] We found that patients with GIST respond to IM therapy irrespective of expression levels of KIT, as evidenced by both a decrease in tumor size and in tumor density (Fig. 2A-D). Although previous reports suggest that weak KIT staining could be due to technical artifact,[30] in the current study we found that 10% of GIST patients demonstrated a weakly positive KIT immunostaining pattern (Table 2). Differences in scoring criteria between studies will account for some differences in positivity thresholds, and the use of different antibodies and antigen retrieval methods will also affect overall rates of positivity. Nonetheless, we found that patients with weak KIT expressing GISTs have a similar PFS with IM therapy compared with patients whose tumors express KIT with greater intensity. Our larger study confirms previous reports of patients with GIST who responded to IM treatment despite the near absence of KIT expression in 2 different samples of the tumor.[21] These findings confirm that GISTs may have very low levels of KIT expression.[20] Moreover, our patients with low levels of KIT expression appeared to demonstrate a trend toward a better median PFS time from IM therapy as those patients whose tumors expressed higher levels of KIT by immunohistochemistry, and we believe that the analysis did not reach significance due to the limited size of the sample. Additional studies on larger population samples will therefore be needed to validate this observation.

The intensity of immunostaining in the histopathologic samples was assessed by comparing the intensity of tumor cells (Fig. 1C and 1D), and a biased interpretation between observers may occur. Similar to previous reports, the majority of tumors in the current study expressed CD34 and SMA, but were negative for desmin and S-100 protein.[5,25,26,31] We have also shown that the presence of CD34, desmin, SMA, and S-100 protein in GIST from patients treated with IM had no significant impact on the PFS in patients treated with IM (Tables 2 and 3).

Many patients with advanced GIST have benefited from the use of IM. Before the widespread use of IM, the prognosis for patients with primary GIST was assessed by using tumor size and mitotic activity. Important prognostic information from an analysis of pathologic features has been proposed.[25,26] Although there were many prognostic features for GIST before IM, the relevancy of these prognostic features in the era of IM therapy is not currently known. Importantly, our data suggest that weak KIT staining is not a negative prognostic feature in patients with advanced GIST who are treated with IM. Although our results in the current study may appear counterintuitive, recent reports have shown similar findings in patients with advanced nonsmall cell lung carcinoma treated with gefitinib. These published results have shown that the level of epidermal growth factor receptor (EGFR) expression is not a significant predictive factor for a therapeutic benefit from gefitinib. Although only a small number of patients responded to this agent, there were no significant differences noted in response rates or survival by the weak or strong tumoral expression of EGFR by immunohistochemistry. However, the investigators noted that the subset of patients with adenocarcinoma whose tumors displayed 2+ or 3+ EGFR intensity were found to have an 80% response rate, whereas those patients whose adenocarcinoma had no or 1+ intensity of EGFR were found to have only a 20% response rate ($P = .009$).[32] Moreover, there also appears to be a level of HER-2/*neu* expression that correlates with response rates when patients with adenocarcinoma of the breast are treated with trastuzumab. Investigators reported a 48% response rate in patients whose breast tumor expresses 3+ levels of HER-2/*neu* compared with response rates of 7% with 2+ HEr-2/*neu* expression by immunohistochemistry.[33] In the context of our study of KIT intensity in GIST, it is interesting to speculate that the correlation of benefit from a tyrosine kinase inhibitor to levels of target expression is specific to adenocarcinoma. Thus, in the case of GIST, even low levels of the mutant receptor may be sufficient to phosphorylate downstream signaling pathways and drive tumorigenesis, whereas higher levels of kinase are required in the case of HEr-2/*neu* or EGFR.

The results from the current study suggest that patients whose GISTs exhibit very low levels of KIT expression by immunohistochemistry benefit from IM therapy. Moreover, the presence of desmin or S-100 protein does not exclude patients from the diagnosis of GIST and, although rare in the case of desmin, these patients appear to benefit from IM therapy. Therfore, these GIST patients should not be excluded from clinical trials or standard therapy with IM.

REFERENCES

1. Kindblom LG, Meis-Kindblom J, Bumming P, et al. Incidence, prevalence, phenotype and biologic spectrum of gastrointestinal stromal tumors (GIST)—A population-based study of 600 cases. *Ann Oncol.* 2003;13(Suppl 5):157.
2. Clary BM, DeMatteo RP, Lewis JJ, Leung D, Brennan MF. Gastrointestinal stromal tumors and leiomyosarcoma of the abdomen and retroperitoneum: a clinical comparison. *Ann Surg Oncol.* 2001;8:290–299.
3. Gottleib J, Baker L, O'Bryan R, et al. Adriamycin (NSC-123-127) used alone and in combination for soft tissue and bony sarcomas. *Cancer Chemother Rep.* 1974;6:271–282.
4. Trent JC, Beach J, Burgess MA, et al. A two-arm phase II study of temozolomide in patients with advanced gastroin-

testinal stromal tumors and other soft tissue sarcomas. *Cancer*. 2003;98:2693–2699.
5. Demetri GD, von Mehren M, Blanke CD, et al. Efficacy and safety of imatinib mesylate in advanced gastrointestinal stromal tumors. *N Engl J Med*. 2002;347:472–480.
6. van Oosterom AT, Judson I, Verweij J, et al. Safety and efficacy of imatinib (STI571) in metastatic gastrointestinal stromal tumours: a phase I study. *Lancet*. 2001;358:1421–1423.
7. van Oosterom AT, Mouridsen HT, Nielsen OS, et al. Results of randomised studies of the EORTC Soft Tissue and Bone Sarcoma Group (STBSG) with two different ifosfamide regimens in first- and second-line chemotherapy in advanced soft tissue sarcoma patients. *Eur J Cancer*. 2002;38:2397–2406.
8. Rankin C, von Mehren M, Blanke C, et al. Dose effect of imatinib in patients with metastatic GIST — a phase III sarcoma group study S0033. *Proc Am Soc Clin Oncol*. 2004;23:815.
9. Verweij J, Casali PG, Zalcberg J, et al. Progression-free survival in gastrointestinal stromal tumours with high-dose imatinib: randomised trial. *Lancet*. 2004;364:1127–1134.
10. Fletcher CD, Berman JJ, Corless C, et al. Diagnosis of gastrointestinal stromal tumors: a consensus approach. *Int J Surg Pathol*. 2002;10:81–89.
11. Miettinen M, Lasota J. Gastrointestinal stromal tumors—definition, clinical, histological, immunohistochemical, and molecular genetic features and differential diagnosis. *Virchows Arch*. 2001;438:1–12.
12. Miettinen M, Sobin LH, Lasota J. Gastrointestinal stromal tumors of the stomach: a clinicopathologic, immunohistochemical, and molecular genetic study of 1765 cases with long-term follow-up. *Am J Surg Pathol*. 2005;29:52–68.
13. Antonescu CR, Sommer G, Sarran L, et al. Association of KIT exon 9 mutations with nongastric primary site and aggressive behavior: KIT mutation analysis and clinical correlates of 120 gastrointestinal stromal tumors. *Clin Cancer Res*. 2003;9:3329–3337.
14. Heinrich MC, Blanke CD, Druker BJ, Corless CL. Inhibition of KIT tyrosine kinase activity: a novel molecular approach to the treatment of KIT-positive malignancies. *J Clin Oncol*. 2002;20:1692–1703.
15. Hirota S, Isozaki K, Moriyama Y, et al. Gain-of-function mutations of c-kit in human gastrointestinal stromal tumors. *Science*. 1998;279:577–580.
16. Lasota J, Wozniak A, Sarlomo-Rikala M, et al. Mutations in exons 9 and 13 of KIT gene are rare events in gastrointestinal stromal tumors. A study of 200 cases. *Am J Pathol*. 2000;157:1091–1095.
17. Rubin BP, Singer S, Tsao C, et al. KIT activation is a ubiquitous feature of gastrointestinal stromal tumors. *Cancer Res*. 2001;61:8118–8121.
18. Heinrich MC, Corless CL, Duensing A, et al. PDGFRA activating mutations in gastrointestinal stromal tumors. *Science*. 2003;299:708–710.
19. Heinrich MC, Corless CL, Demetri GD, et al. Kinase mutations and imatinib response in patients with metastatic gastrointestinal stromal tumor. *J Clin Oncol*. 2003;21:4342–4349.
20. Bauer S, Corless CL, Heinrich MC, et al. Response to imatinib mesylate of a gastrointestinal stromal tumor with very low expression of KIT. *Cancer Chemother Pharmacol*. 2003;51:261–265.
21. Medeiros F, Corless CL, Duensing A, et al. KIT-negative gastrointestinal stromal tumors: proof of concept and therapeutic implications. *Am J Surg Pathol*. 2004;28:889–894.
22. Singer S, Rubin BP, Lux ML, et al. Prognostic value of KIT mutation type, mitotic activity, and histologic subtype in gastrointestinal stromal tumors. *J Clin Oncol*. 2002;20:3898–3905.
23. Kaplan E, Meier P. Nonparametric estimation from incomplete observations. *J Am Stat Assoc*. 1958;53:457–481.
24. Cox D. Regression models and life tables (with discussion). *J R Stat Soc*. 1972;34:187–220.
25. Berman J, O'Leary TJ. Gastrointestinal stromal tumor workshop. *Hum Pathol*. 2001;32:578–582.
26. Fletcher CD. Clinicopathologic correlations in gastrointestinal stromal tumors. *Hum Pathol*. 2002;33:455.
27. Dileo P, Rankin CJ, Benjamin RS, et al. Incidence and reasons for dose modification of standard-dose vs. high-dose imatinib mesylate (IM) in the phase III Intergroup Study S0033 of patients (pts) with unresectable or metastatic gastrointestinal stromal tumor (GIST). *J Clin Oncol*. 2005;23:824S–824S.
28. Rankin C, Von Mehren M, Blanke C, et al. Dose effect of imatinib (IM) in patients (pts) with metastatic GIST — phase III Sarcoma Group Study S0033. *J Clin Oncol*. 2004;22:819S–819S.
29. Choi H, Charnsangavej C, de Castro Faria S, et al. CT evaluation of the response of gastrointestinal stromal tumors after imatinib mesylate treatment: a quantitative analysis correlated with FDG PET findings. *AJR Am J Roentgenol*. 2004;183:1619–1628.
30. Hornick JL, Fletcher CD. Immunohistochemical staining for KIT (CD117) in soft tissue sarcomas is very limited in distribution. *Am J Clin Pathol*. 2002;117:188–193.
31. Hurlimann J, Gardiol D. Gastrointestinal stromal tumours: an immunohistochemical study of 165 cases. *Histopathology*. 1991;19:311–320.
32. Parra HS, Cavina R, Latteri F, et al. Analysis of epidermal growth factor receptor expression as a predictive factor for response to gefitinib ('Iressa', ZD1839) in non-small-cell lung cancer. *Br J Cancer*. 2004;91:208–212.
33. Vogel CL, Cobleigh MA, Tripathy D, et al. Efficacy and safety of trastuzumab as a single agent in first-line treatment of HER2-overexpressing metastatic breast cancer. *J Clin Oncol*. 2002;20:719–726.